



HAL
open science

The periosteum dilemma in bioarcheology: Normal growth or pathological condition? – 3D discriminating microscopic approach

Charlotte Ritemard, Antony Colombo, Pascal Desbarats, Bruno Dutailly, Olivier Dutour, H el ene Coqueugniot

► To cite this version:

Charlotte Ritemard, Antony Colombo, Pascal Desbarats, Bruno Dutailly, Olivier Dutour, et al.. The periosteum dilemma in bioarcheology: Normal growth or pathological condition? – 3D discriminating microscopic approach. *Journal of Archaeological Science: Reports*, 2019, 24, pp.236-243. <10.1016/j.jasrep.2018.12.012>. <halshs-02162366>

HAL Id: halshs-02162366

<https://shs.hal.science/halshs-02162366v1>

Submitted on 8 Dec 2020

HAL is a multi-disciplinary open access archive for the deposit and dissemination of scientific research documents, whether they are published or not. The documents may come from teaching and research institutions in France or abroad, or from public or private research centers.

L'archive ouverte pluridisciplinaire **HAL**, est destin e au d p t et   la diffusion de documents scientifiques de niveau recherche, publi s ou non,  manant des  tablissements d'enseignement et de recherche fran ais ou  trangers, des laboratoires publics ou priv s.



HAL Authorization

Title: The Periosteum Dilemma in Bioarcheology: Normal growth or Pathological condition?
– 3D discriminating microscopic approach

Short title: The Periosteum Dilemma - 3D discriminating approach

Authors: RITTEMARD Charlotte^{1,2*}, COLOMBO Antony^{1,2}, DESBARATS Pascal³,
DUTAILLY Bruno¹, DUTOUR Olivier^{1,2,4} & COQUEUGNIOT H el ene^{1,2,5}

Abstract:

Objective: Periosteal reactions are frequently used as a proxy for past populations' health. However, macroscopic evidence of periosteal activity observed on infant's dry bones can be difficult to interpret in terms of normal growth process or pathological changes. This could lead to over-interpretation of a poor health status during childhood in past populations.

The aim of our study is to propose new distinctive micro-morphological criteria to differentiate between non-adult dry bones presenting physiological sub-periosteal bone growth and periosteal reaction due to pathological conditions.

Material and methods: We sampled 12 perinatal human tibiae from two osteoarcheological collections and proceeded a 3D microstructural analysis of the canal network of cortical bone using micro-CT.

Results: 3D canal network organization in cortical bone allowed us to distinguish physiological from pathological periosteal reactions. Moreover, our study revealed different types of organization of the cortical bone microstructure corresponding to various stages of bone remodeling.

Discussion: This exploratory study shows the advantages of a non-destructive microscopic analysis using 3D imaging of the cortical canal network organization in order to distinguish between physiological and pathological bone production during early growth. This will contribute to a better understanding of past populations' epidemiology.

Keywords: periosteal reaction, μ -CT, cortical bone canal network, paleopathology, infants.

Corresponding author:

Charlotte Rittemard

EPHE, PSL University, UMR 5199 PACEA, CNRS-Universit e de Bordeaux, France

+33647548812

charlotte.rittemard@etu.ephe.fr

¹ UMR 5199 PACEA, Universit e de Bordeaux, all e Geoffroy Saint Hilaire, 33615 Pessac cedex, France

²  cole Pratique des Hautes  tudes, EPHE, PSL Universit e, 75014 Paris, France

³ UMR 5800 LaBRI, Universit e de Bordeaux, 351 Cours de la Lib eration, 33405 Talence, France

⁴ Department of Anthropology, University of Western Ontario, 1151 Richmond Street, London, Ontario, Canada

⁵ Department of Human Evolution, Max Planck Institute for Evolutionary Anthropology, Deutscher Platz 6, 04103 Leipzig, Germany

Introduction

Sub-periosteal bone production, commonly referred to as periosteal reactions, are used by anthropologists and bioarcheologists as a proxy for ancient populations' health status (Brickley and Ives, 2006 and 2008; Brown and Ortner, 2011; Steckel and Rose, 2002; Weston, 2009). These periosteal reactions are easily identifiable on dry bone. Their presence on adults' bones are reliably associated with a pathological condition, although often non-specific, as the periosteal region is physiologically inactive on mature skeletons. However, their interpretation on perinates' bones is more challenging.

Indeed, for infants, periosteal reactions may both reflect a pathological phenomenon or a physiological episode of sub-periosteal growth. Shopfner (1966) raised this issue when he examined radiographs of long bones for 410 children, including 335 full-term infants (under 6 months of age) and 75 premature subjects. He carried out a longitudinal analysis on part of the subjects, allowing him to study the phenomenon through time. This author concluded that the presence of sub-periosteal bone appositions observed on radiographs of children aged between 1 and 6 months is both common and normal. Indeed, normal growth can provoke periosteal reactions, due to an episode of high vascularization and cellular activity. Previously, Hancox *et al.* (1951) described a rapid and intense process of bone deposition in young children that they interpret as a local acceleration of bone growth.

Both Shopfner (1966) and Hancox *et al.* (1951) warned against the risk to misinterpret normal aspect of periosteal activity in very immature individuals. Yet, in forensic medicine, the confusion between periosteal reactions due to child abuse and simple rapid episodes of physiological growth can lead to serious legal consequences (Plunkett and Plunkett, 2000; De Silva, 2003). Similarly, in biological anthropology and bioarcheology, the distinction between normal and pathological aspects of periosteal reactions is crucial to interpret correctly the health status of past populations.

Macroscopic analysis is the common way to study periosteal reactions on the bone surface of osteoarcheological material. Several classifications have been proposed (Cook, 1976; Lallo, Armelagos and Rose, 1978; Lé *et al.*, 2006; Mensforth *et al.*, 1978). However, the main issue is that these criteria do not consider internal bone structures. Therefore, Weston recommended to combine these analyses with X-rays in order to observe the internal bone structure. This allows detecting periosteal reactions that are not macroscopically visible (Weston, 2004 and 2008). However, X-ray images display a superimposition of layers, making difficult the visualization of internal structures independently and accurately. For periosteal reactions, they do not enable the identification of a specific disorder; therefore they do not represent a better diagnostic tool (Weston, 2008). This first level of analysis is not enough to study periosteal reactions: some changes are not expressed macroscopically and the same aspect can correspond to different diagnoses.

Regarding the youngest age category among ancient populations, Ribot and Roberts (1996) recommended to not use this age group for bioarcheological studies on non-specific stress indicators. Especially, they consider the 0-1 year age group as being non-adequate to analyze macroscopic periosteal reactions. For this age group, they recommend the use of microscopic observations.

Microscopic analysis of bone using histological techniques have been considered to provide more accurate and reliable diagnoses. On dry bone, Schultz developed specific methods for paleohistology and claimed that it is possible to distinguish different pathological causes of periosteal reactions based on histological sections (Schultz, 2001). Contradictory results were obtained by Weston (2009) who used the same technique to study the Saint George Hospital museum collection. She found that the distinction was not as obvious as Schultz argued and concluded that paleohistology does not actually offer decisive information on periosteal reaction etiology.

Therefore, alternative methods such as micro-computed tomography (μ CT) could provide new elements on this issue (Cooper *et al.*, 2003 and 2007; Harrison and Cooper, 2015). μ CT combines the advantages of radiology and histology without the specific disadvantages: it allows access to inner bone structures and microstructure without superimposition, and it does not necessitate any destruction of the sample. Accordingly, μ CT acts as a non-invasive alternative to histology for bone microstructure study. Moreover, the improved resolution of acquisitions allows using μ CT to analyze very thin structures such as cortical bone canals.

The goal of our study, as a feasibility study, is to analyze an osteoarcheological sample of individuals younger than one year of age using μ CT in order to assess if microstructural criteria by describing the organization, repartition and quantification of the cortical canals (detailed in the Methods section), can help to differentiate normal periosteal activity from a pathological one.

MATERIAL AND METHODS

Material

This feasibility study has been carried out on osteoarcheological samples. This material allowed us to avoid any ethical issues regarding biomedical studies on children. Moreover, identified skeletons collections providing infra-cranial perinates' bones are extremely scarce, making μ CT analysis difficult to perform.

Two osteoarcheological collections of Montlouis (Charente Maritime, France) and Saint-Gilles (Gard, France) were selected. The collection of Montlouis is dated from the 1st to 3rd century AD and it is composed of 200 burials including 56 burials of infants aged from 0 to 1-year-old (Sachau, 2008). The collection of Saint-Gilles is dated from the 15th to 19th century and it is composed of 162 individuals including 17 aged from less than 1 year old (Demangeot *et al.*, 2016). Differences in geographic, chronological, social and economic parameters between these two series allowed us to minimize the possible idiosyncratic effect of a single collection analysis.

Among the 73 infant skeletons, we selected a sample of 12 individuals, presenting a good state of preservation and showing periosteal reactions. Preservation was quantified using specific indices (bone quality and anatomical conservation) previously defined (Dutour, 1989; Bello, *et al.*, 2006). Individual age was estimated by a method using maximum bone length measurements of known age fetal series (Adalian *et al.*, 2002). Age at death among our sample ranged from 30 to 42 weeks of amenorrhea (Table 1). This category of age is relevant for our topic as it corresponds to a period of life during which the periosteum is extremely active (Cameron, 2002; Ribot and Roberts, 1996). We selected the tibia, which is the bone showing the highest prevalence of periosteal reactions, ranging from 22% (Hancox *et al.*, 1951) to 46% (Kwon, Spevak and Fletcher, 2002) for immature subjects. Bone surface observations have been performed using a Leica® Z16APO microscope.

Periosteal reactions were selected among the stages 1 to 4 of the method proposed by Lé *et al.* (2006) to categorize periosteal reactions. All selected individuals but one (131) do not show any evidence of pathological conditions on other parts of the skeleton. The material selected for the μ CT analysis is presented in Table 1.

All the bones selected for this study, with the exception of tibia 115, show a porous aspect corresponding to diffuse sub-periosteal bone production expanded on the antero-medial aspect of the diaphysis. Individuals 2545, 94 and 107 exhibited a reaction spreading to the posterior or postero-medial part of the diaphysis, while individual 2524B showed an involvement of its antero-lateral aspect. Individual 131 showed periosteal reactions on all the circumference of the tibia diaphysis.

Table 1: List of sampled individuals according to estimated age and preservation indices (BQI = bone quality index (Bello, 2001; Bello et al., 2003); API = anatomical preservation index (Dutour, 1989; Bello et al., 2006))

Individuals	Age (weeks of Amenorrhea)	BQI	API
Montlouis:			
Sp. 2265	36 - 38	0,75	75-100%
Sp. 2430	36 - 38	1	75-100%
Sp. 2524A	36 - 38	0,75	75-100%
Sp. 2524B	36 - 38	1	50-75%
Sp. 2545	38 - 40	0,75	50-75%
Sp. 2654	38 - 40	1	100%
Saint-Gilles:			
Sp. 94	32 - 36	1	75-100%
Sp. 107	40	1	100%
Sp. 115	30 - 34	1	100%
Sp. 131	36 - 40	1	100%
Sp. 163A	34 - 38	0,75	75-100%
Sp. 184	36 - 42	1	100%

Method

μ CT analysis provides a better visualization of some pathological processes compared to 2D histological observation (Coqueugniot *et al.*, 2015). Besides, as cortical bone is organized in 3D (Stout *et al.*, 1999), it is more informative to observe its structure in three dimensions. The region of interest (ROI) for the 3D reconstructions and bone microstructural analysis is the lateral area of the proximal part of the tibia, near the nutrient foramen (Figure 1). We selected this specific area for its good state of preservation and the high prevalence of periosteal reaction it presented within our sample.

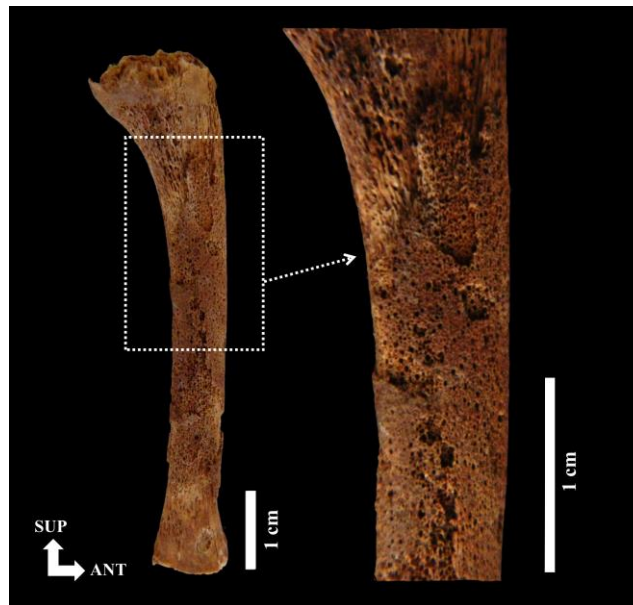


Figure 1: Region of interest for study (medial view of left tibia – individual # 131 from the Saint-Gilles collection)

μ CT acquisitions were performed using a Phoenix Nanotom S[®] (General Electric) with a resolution ranging from 9 to 12 μ m depending of the size of the bone.

Treatment of μ CT-scans was carried out using the software TIVMI[®] (Dutailly *et al.*, 2009). A specific protocol was established (Figure 2): (i) selection of the ROI, (ii) segmentation using the semi-automated segmentation function of TIVMI[®] in order to extract the cortical canal network, (iii) 3D reconstruction of the canal network using TIVMI[®] 3D High Maximum Height (HMH) algorithm¹, (iv) network ‘skeletonization’ using a specific thinning algorithm that gradually removes pixels from the objects contour, leaving only its ‘skeleton’ (Attali, 1995; Plougonven, 2009). The ‘skeleton’ is a simplified version of the object while preserving its topology. The 3D ‘skeletons’ of cortical bone canal network were reconstructed with the Serra’s mathematical morphology algorithm (Serra, 1983 and 1988).

¹The 3D reconstruction delimits the external walls of the intra-cortical canal network, meaning that the space which appears virtually “empty” around the network is actually constituted of Haversian compact bone tissue.

The qualitative parameters chosen allow the description of the general organization and repartition of the canals within cortical bone. The first parameters (Figure 3a) is the relative thickness of the sub-periosteal region with three grades: none, intermediate, larger than one fourth of total cortical thickness. The second parameter (Figure 3b) is the ROI organization, described as simple (single bone and canals organization type) or complex (zonal organization). The third parameters (figure 3c) describes the continuous presence of canals inside the ROI or presence of zones without canals (non-continuous).

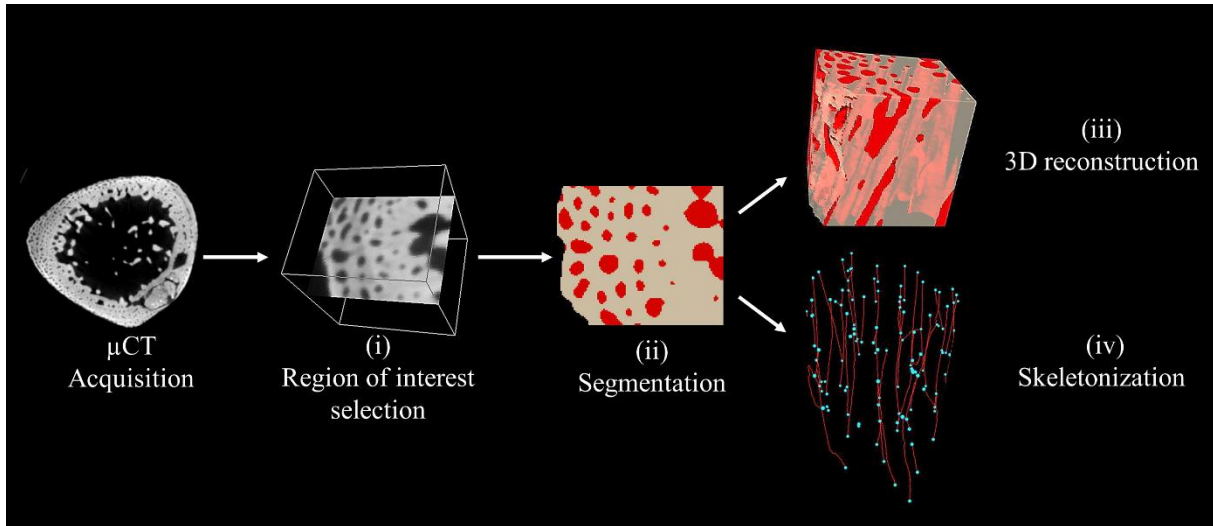


Figure 2: Protocol used for 3D analysis of μ -CT data (on the 2D slice and 3D reconstruction, the cortical network is in red)

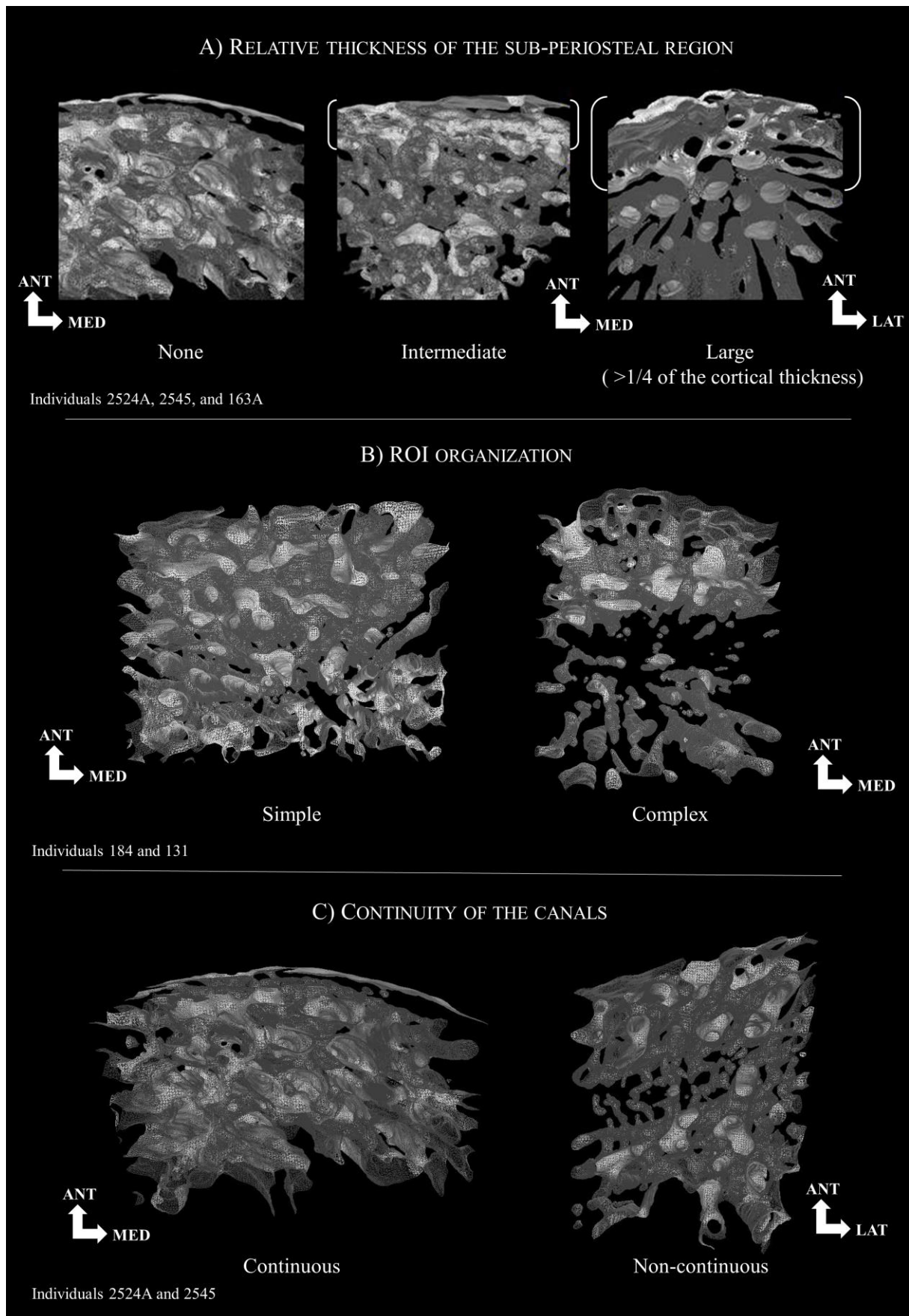


Figure 3: Qualitative parameters

The following quantitative parameters have been chosen because they are classically used to quantify the cortical bone structure in histomorphometry. These parameters and their abbreviations are well defined in the updated article of Dempster *et al.*, (2013). Moreover the histomorphometrical parameters characterizing bone structure are totally transposable to μ CT studies (Fajardo et al., 2002). The parameters analyzed in our study are the total bone volume (TV, mm^3), the canal volume (Ca.V, mm^3), the cortical porosity (Ca.V/TV), the connectivity (Ca.ConnD, mm^{-3}) – connectivity is the number of connections between canals per unit of volume – , the number of canals (Ca.N, mm^{-3}) – it corresponds to the total canals number per unit of volume – , and the ratio between the number of unconnected canals inside the volume and the total number of canals (Ca.unConn.N/Ca.N).

Statistical analysis

The μ CT data were analyzed using a Factorial Analysis of Mixed Data (FAMD) taking all qualitative and quantitative parameters into account, by using *FactoMineR* package (Lê and Husson, 2008) implemented in the R[®] (v. 3.4.4) statistics software. With this package it is also possible to perform a clustering to identify groups statistically different.

RESULTS:

Individual's qualitative and quantitative parameters are shown in Table 2 and their analysis by FAMD is presented in Figure 4. Dim 1 represents 27.8% of the variability, reflecting sub-periosteal region thickness, connectivity, cortical porosity and the ratio between unconnected canals/canal numbers. Dim 2 represents 25.45% of the total variability and is influenced by canal number, continuity and organization of the ROI. This analysis clearly distributes the individuals of our sample within four clusters identified by the software R. The calculated link between the clusters division and the parameters analyzed provide a p-value of 0.0003 for the dimension 1 and 0.0002 for the dimension 2 showing the high level of distinction between the clusters.

Table 2: qualitative and quantitative results (nomenclature after Parfitt et al., 1987 and Dempster et al., 2013) TV : total volume, Ca.V : canal volume ; Ca.V/TV : cortical porosity, ConnD : connectivity, Ca.N: canal number, Ca.unConn.N/ Ca.N: ratio of unconnected canals by total canal number.

Individuals	Continuity	Organization	Sub-periosteal region thickness	TV (mm ³)	Ca.V (mm ³)	Ca.V/TV	ConnD (mm ⁻³)	Ca.N (mm ⁻³)	Ca.unConn.N (mm ⁻³)	Ca.unConn.N/CA.N
S. 2265	Discontinuous	Homogeneous	None	2,091	0,336	0,161	22,956	10,043	0	0
Sp. 184	Continuous	Homogeneous	None	2,659	0,435	0,164	53,404	28,206	1,128	0,040
S. 2430	Continuous	Homogeneous	Intermediate	3,199	0,671	0,21	51,266	27,821	1,25	0,045
S. 2524A	Continuous	Homogeneous	None	1,253	0,214	0,171	44,693	30,327	3,99	0,132
S. 2654	Continuous	Homogeneous	None	1,227	0,319	0,26	34,23	31,785	0	0
S. 2524B	Continuous	Homogeneous	Intermediate	2,079	0,274	0,132	63,492	25,012	0	0
S. 2545	Discontinuous	Heterogeneous	Intermediate	2,013	0,55	0,273	97,367	30,8	0	0
Sp. 94	Continuous	Heterogeneous	Large	2,32	0,69	0,297	8,621	21,552	14,224	0,660
Sp. 107	Continuous	Heterogeneous	None	2,704	0,535	0,198	69,157	20,34	0	0
Sp. 115	Continuous	Heterogeneous	None	0,68	0,156	0,229	19,118	25	11,765	0,471
Sp. 131	Discontinuous	Heterogeneous	Large	2,624	0,5	0,19	31,631	28,201	3,811	0,135
Sp. 163A	Continuous	Heterogeneous	Large	1,325	0,333	0,251	19,623	18,868	5,283	0,280

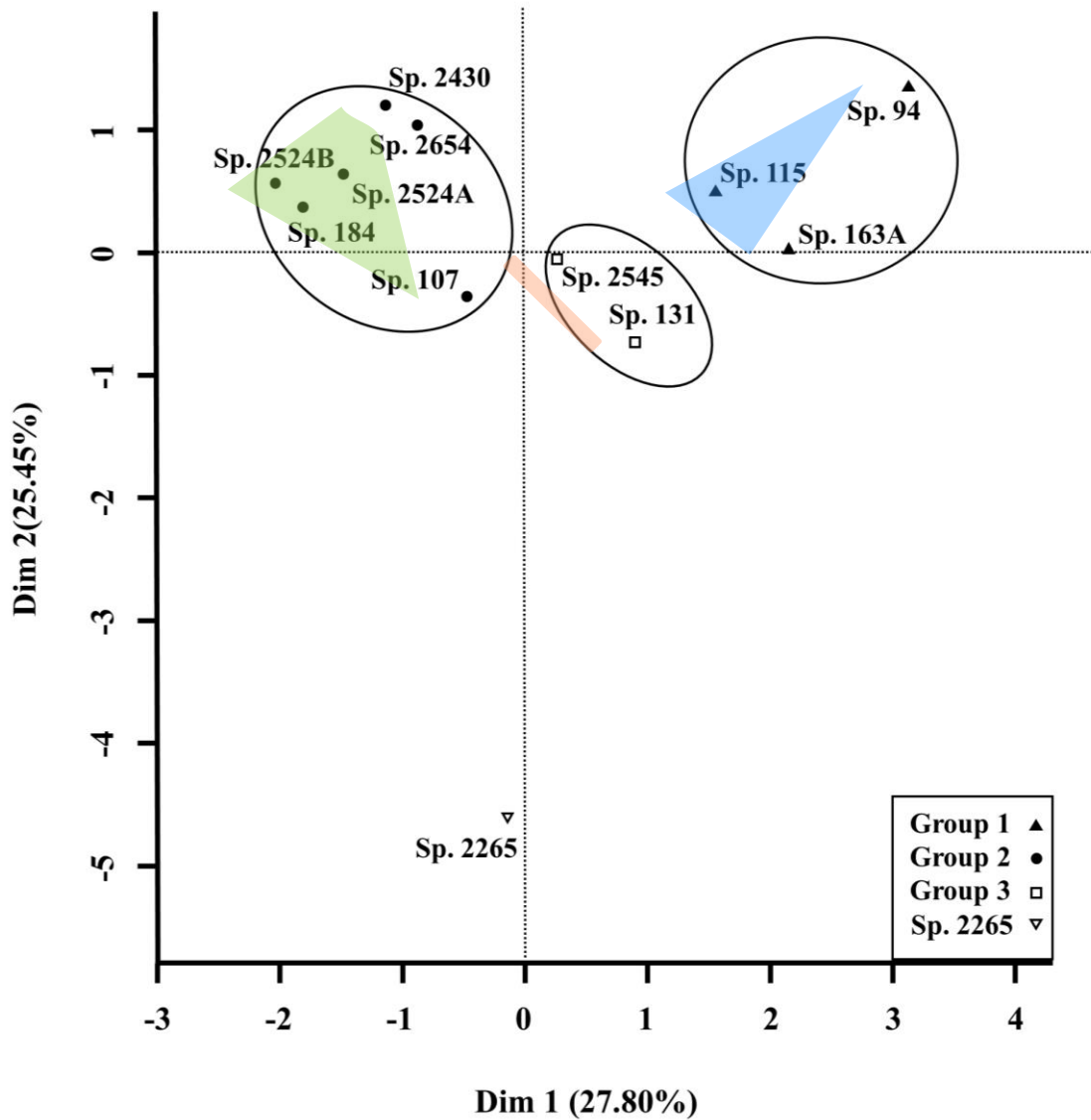


Figure 4: Factorial Analysis of Mixed Data (FAMD)

Group 1 contains individuals 94, 115 and 163A. They present a complex canal distribution in the ROI with a continuous pattern and large or intermediate active periosteal area (Table 2). Moreover, these individuals have in common a high canal number, a high proportion of unconnected canals, a high cortical porosity and a low connectivity (Table 2).

The sub-periosteal region of individuals 163A and 94 is organized in visible successive layers of bone (Figure 5). The canals form parallel lines on the bone external surface. Moreover, we observed a gradient in canal size, decreasing from endosteal to periosteal areas except for the last rows of canals, in the subperiosteal part of the bone, which is larger than the canals located in the middle of the ROI. Individual 115 presents an alignment of canals, but these canals are smaller on the whole ROI.

Figure 5:

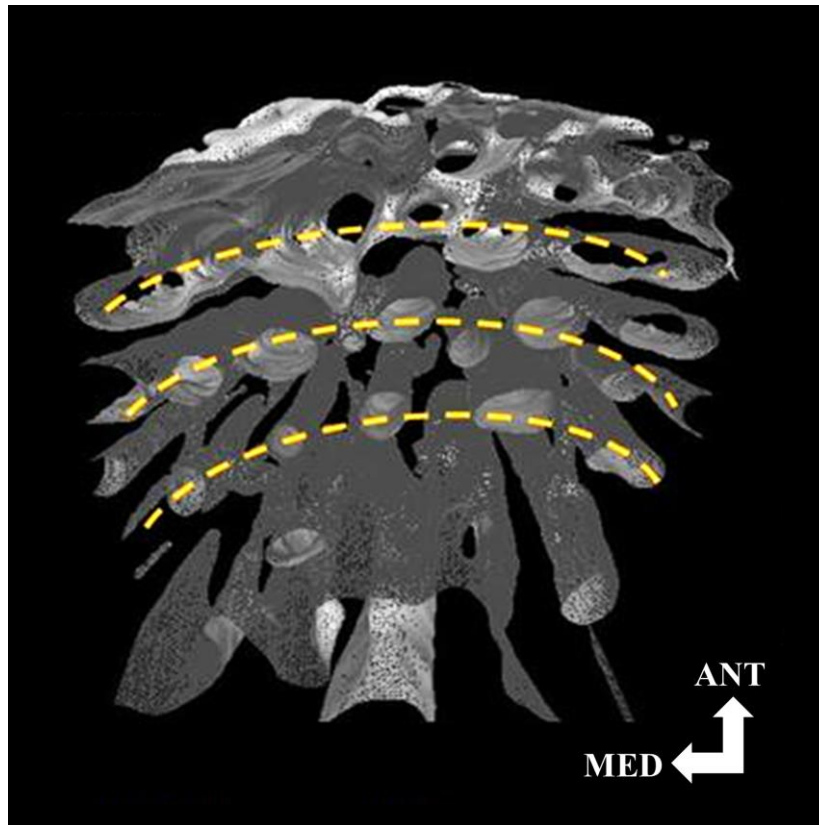

Figure 5: ROI Reconstruction of individual 163A (superior view). The dot lines represent the circumferential rows of canals, parallel to the periosteal bone surface

Group 2 brings together individuals 2430, 2654, 2524A, 2524B, 107 and 184 (Figure 4). These individuals ROIs are defined by a simple canal distribution in the ROI with a continuous pattern but no or intermediate active periosteal area. Besides, these individuals show a high canal number and connectivity but a low cortical porosity and no or few unconnected canals. Within this group, individual 107 distinguishes itself by a lower canal number.

Group 3 is composed of individuals 2545 and 131, which share a complex organization with a discontinuous pattern and large active periosteal area. These individuals present a low canal number and connectivity associated with an intermediate ratio of unconnected canals and cortical porosity (Figure 4).

The canals located on the sub-periosteal bone of individual 131 have a more disorganized appearance than individual 2545 and show an important number of connections (Figure 3b-c).

Individual 2265 appears isolated from the rest of the sample. It is characterized by a complex organization with a discontinuous pattern and no active periosteal area. This individual presents a very low canal number, intermediate cortical porosity, a high connectivity and no unconnected canals (Table 2). The canals' orientation shows a less longitudinal pattern with a stronger contrast in canal size which is predominantly large (Figure 6).

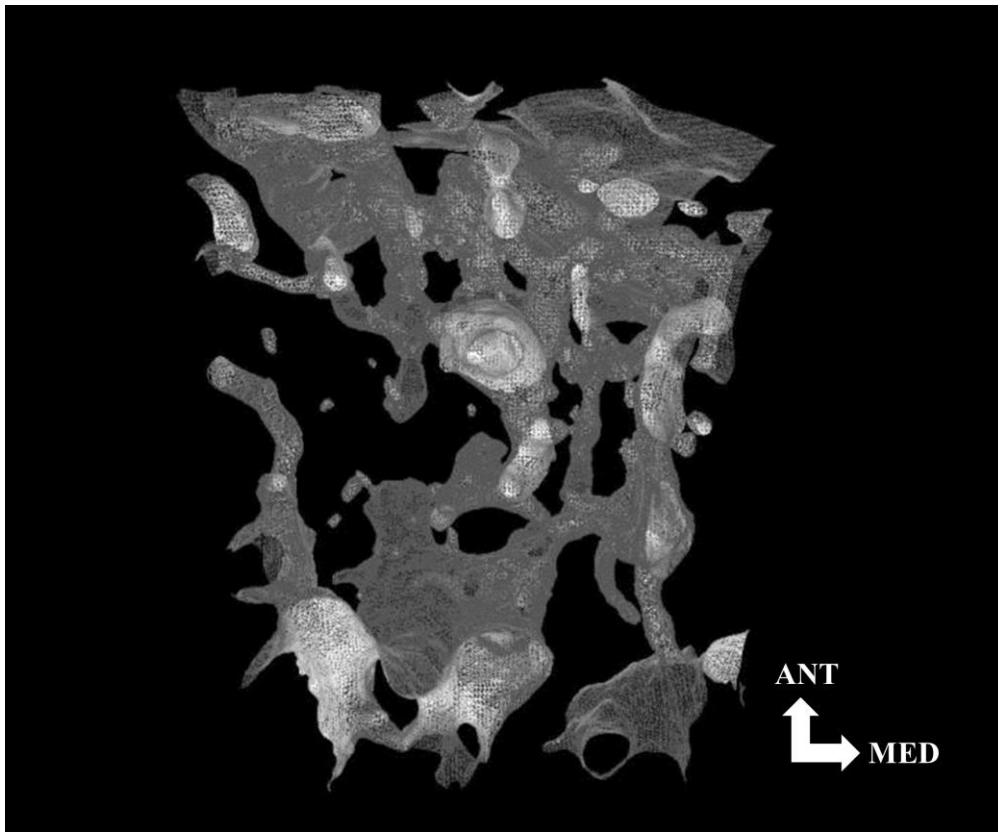


Figure 6: ROI Reconstruction of individual 2265 (superior view)

DISCUSSION:

Our sample is divided in 3 groups in the ACP, related to the first dimension, one individual is distinguished according to the second dimension. This shows the importance and interest of some microstructural criteria such as sub-periosteal region thickness, connectivity and the proportion of unconnected canals, in the assessment and interpretation of periosteal reactions. The variations observed for the sub-periosteal region thickness, for instance, reflect different sub-periosteal activity phases of the growth process. Among the cases of active growth, two patterns emerged. The first one, illustrated by the subjects 163A and 94, corresponds to successive layers of bone deposited by the periosteum, parallel to the external bone surface. This organization of lamellar bone is similar to the physiological growth process (Schaeffer, 1989). The 3D reconstructions showed variations in canal size for these subjects (Figure 5). Indeed, the canals located on the edge of the bone surface are large and then, the canal diameter gradually decreases as the distance from the edge of the bone surface increases. Yet, according to Rauch *et al.* (2007), the diameter of cortical bone canals should remain constant during bone development. However, their study was carried out on a sample of living individuals allowing them to distinguish the superimposition of concentric bone layers forming the osteons as well as non-mineralized osteoid tissue. For bone tissue found in archaeological context, the osteoid matrix has disappeared. It is, therefore, possible that the differences in diameter within a ROI we observed in this study actually correspond to different osteoid mineralization stages. The large canals located under the periosteum could correspond to the newly formed osteons with a non-mineralized osteoid. In contrast, the smallest canals located in the deeper layers of the cortical bone would represent older osteons, with already mineralized osteoid.

Individual 131 and 2545 exhibit a completely different pattern: they share with group 1 a complex organization and large sub-periosteal region activity but the ROI of these two individuals contains fewer canals for a higher connectivity. Also both individual 131 and 2545 display a region, in the middle of the ROI, without canals, dividing the ROI in two. This specific region might correspond to an episode of cessation of bone growth. Indeed, human growth is known as a saltatory process (Lampl, 1993). In the case of individual 2545, the two regions on each side of the cessation are similar with an average number of connected canals. On the contrary individual 131 demonstrates different organizations. Thus, the internal part of the cortical bone contains few longitudinal canals with very few connections similar to the structure observed in individuals from group 1. The external part shows a disorganized bone production with a high number of canals and connections that highly suggest an episode of sudden resumption of growth. For this individual, the number of connections (31.631 mm^3) and the number of canals (28.2 mm^{-3}) are comparable to those obtained for group 2. Besides, the bone production process noted for subject 131 corresponds to a rapid deposition of immature bone and, in association with the disorganized structure, suggests a pathological process. This hypothesis is supported by other pathological signs recorded on the bones of individual 131: a narrowing of the medullar cavity of the long bones and densification of all metaphyseal regions (Demangeot *et al.*, 2016). Moreover, the sub-periosteal production observed on this individual shows changes that are similar to those described by Schultz as being associated with inflammatory processes (Schultz, 2001).

Furthermore, Cooper *et al.* (2003, 2007) suggested that cortical bone remodeling results in an increase in Haversian canals number and connections number. The variations observed in our sample for these parameters would then reflect different remodeling stages. Besides, according to Rauch *et al.* (2007), intra-cortical remodeling varies during development and if so, it is possible that individuals of our sample illustrate different stages of cortical bone development. Thus, individuals from group 2, presenting the highest values of connectivity (up to $97,367 \text{ mm}^{-3}$) and canals number (up to $31,785 \text{ mm}^{-3}$) could correspond to remodeled bone stages while the individuals from group 1 could correspond to a remodeled primary bone composed of longitudinal canals with very few connections.

The criterion of bone microstructure organization seems also to reflect the degree of bone remodeling. Simple organization corresponds to a uniformly remodeled bone, while complex organization reflects an absence of remodeling or disorganized bone production with similar characteristics to the remodeled bone for individual 131.

Individual 2265 appears isolated from the other individuals with a very low canal number. Moreover, these canals seem to be predominantly larger. The isolation of this individual from others and the very specific features of its canals structure raise questions. The organization is connected, as for the individuals from group 2, but the connections number and canals number are significantly lower and do not present the lamellar organization of individuals from group 1 either. This specific organization could demonstrate a pathological development resulting in abnormally important cortical porosity associated with few but large pores. Besides, individual 2265 also shows a gap on the lateral part of the ROI (Figure 6) that introduces the possible action of external agents responsible for bone alterations and mineralization modification (Brugal *et al.*, 2015, Tuner-Walker and Jans, 2008). In this case, we could put forward the hypothesis of a participation of a taphonomic process at the origin of these alterations.

Conclusion:

The results of this exploratory study show interesting insights for the distinction of pathological and physiological bone growth in infants thanks to microstructural cortical bone analysis. Indeed, multivariate analyses of the parameters of cortical bone microstructure discriminate three individuals presenting abnormal organization from the rest of the sample. Among them, individual 131 presented clear evidence of a pathological condition. Moreover, the parameters we selected allowed us to better understand the cortical bone organization. Criteria of connectivity and canal number seem particularly interesting, as well as the simple and continuous aspect of the organization of cortical canals to recognize physiological processes. Then, we identified several stages of bone activity and remodeling. These preliminary results are very encouraging, and highlight the potential of microstructural cortical bone study for understanding skeletal growth processes in past populations. These preliminary results have to be strengthened by extending this approach to reference osteological collections of known age, sex, and pathological conditions. Study of older specimens is also in progress to better understand the effect of age on periosteum activity.

Acknowledgments:

We are grateful to Coralie Demangeot and David Perissinotto from *Hadès Archéologie* for allowing us access to the osteoarcheological collection of Saint-Gilles as well as Patrice Courtaud (UMR 5199 PACEA) for the access to the collection of Montlouis. We are indebted to Géraldine Sachau for providing us her unpublished anthropological study (Master's thesis) on the Montlouis collection.

We thank anonymous reviewers for their helpful comments that improved our manuscript.